To cite this article: Cremonini F, et al. Severe transverse discrepancy in adult Class III patient: Parallel rapid palatal expansion with a bone-borne tandem expansion screws (TSE) followed by lingual fixed appliance for a non-surgical treatment: A case report. International Orthodontics (2021), https://doi.org/10.1016/j.ortho.2021.11.001

International Orthodontics 2020; xx: xxx

Websites:
www.em-consulte.com
www.sciencedirect.com

Case Report

Severe transverse discrepancy in adult Class III patient: Parallel rapid palatal expansion with a bone-borne tandem expansion screws (TSE) followed by lingual fixed appliance for a non-surgical treatment: A case report

Francesca Cremonini [1], Maria Cristina Ansaloni [2], Antonio Cremonini [2], Bartolo Giuliano Maino [1], Emanuele Paoletto [3], Federica Pellitteri [1], Luca Lombardo [1]

Available online:

1. Postgraduate School of Orthodontics, University of Ferrara, Via Luigi Borsari 46, 44121 Ferrara, Italy
2. Private Practice, Corso Adriano 16, 41121 Modena, Italy
3. Lab Orthomodul, Via S. Vincenzo, 61, 36016 Thiene VI, Italy

Correspondence:
Francesca Cremonini, Postgraduate School of Orthodontics, University of Ferrara, Via Luigi Borsari 46, 44121 Ferrara, Italy.
francesca.cremonini@edu.unife.it

Keywords
Lingual appliance
Skeletal Anchorage
Class III
Miniscrew-Assisted Rapid Palatal Expander
MARPE
Miniscrew Assisted Palatal Application
MAPA

Summary

Introduction > Midpalatal suture opening in young adults is often difficult to achieve, depending on the suture maturation stage. It has been suggested that it is possible to avoid surgery and still achieve a successful pure skeletal expansion if a bone-borne Miniscrew-Assisted Rapid Palatal Expander is chosen (MARPE).

Case presentation > The following case report describes the use of a pure bone-borne miniscrew-assisted rapid palatal expander followed by lingual fixed appliance to correct a severe transversal discrepancy in an adult patient characterized by a hyperdivergent mandibular skeletal pattern.

Management and outcomes > All treatment phases were digitally planned, starting with the miniscrews' insertion with a three-dimensionally printed surgical guided (Miniscrew Assisted Palatal Application: MAPA system) and Tandem Skeletal Expander (TSE) appliance, to the lingual indirect bonding. The final outcomes confirmed that this orthodontic approach represented a valid alternative to orthognathic surgery, with a significant improvement of the patient's occlusion and facial appearance.

Discussion > The Tandem Skeletal Expander (TSE) design and the expansion protocol applied allowed to obtain a significant and stable skeletal increase of transversal diameters by digital planning of the insertion of miniscrews, with lower risks and costs than other surgical approaches.

tome xx > 000 > xx 2020
https://doi.org/10.1016/j.ortho.2021.11.001

To cite this article: Cremonini F, et al. Severe transverse discrepancy in adult Class III patient: Parallel rapid palatal expansion with a bone-borne tandem expansion screws (TSE) followed by lingual fixed appliance for a non-surgical treatment: A case report. International Orthodontics (2021), https://doi.org/10.1016/j.ortho.2021.11.001

Introduction

In the field of orthodontics, Rapid maxillary expansion (RME) has been a widely accepted and well-established method in correcting maxillary arch constriction to resolve the posterior crossbite, as well as expanding the arch perimeter to facilitate the resolution of dental crowding [1].

Indeed, it is effective in opening the midpalatal suture when applied before the peak in skeletal growth [2], with minimum molar dental tipping and consequently vertical changes [3].

On the other hand, orthopaedic maxillary expansion can produce unwanted side effects when used in a skeletally mature patient, such as extrusion, periodontal and alveolar bone bending, buccal root resorption, fenestration of the buccal cortex, pain and instability of the expansion [4].

For this reason, for many years, surgical assisted rapid palatal expansion (SARPE) represented the only treatment alternative to facilitate correction of transverse discrepancies in adult patients [5].

As several complications have been reported in literature, including significant haemorrhage, gingival recession, infection, pain, alar base flaring, palatal tissue irritation, and more or less late relapse [6], the clinician and the patient must be aware of all the risks related to this surgical procedure.

Recently, it has been suggested that it is possible to avoid surgery and still achieve a successful pure skeletal expansion if a bone-borne miniscrew-assisted rapid palatal expander is chosen (MARPE) [7,8]. This appliance has a rigid element that connects to the screws, which are inserted into the midpalatal area, delivering the expansion force directly to the suture and maximizing the skeletal effect [9]. MARPE has been successfully used by different authors, which concluded that miniscrew-assisted rapid palatal expander can be used as an effective appliance for correcting maxillary transverse discrepancies in young adults, showing stable outcomes by 1 year after expansion [1,9,10].

An accurate pre-operative planning on volumetric tomography along with the use of a dedicated software, allow the miniscrews to be safely inserted in the appropriate position, by the use of a surgical guide (Miniscrew Assisted Palatal Application, MAPA System) [11]. It is possible to ensure bicortical anchorage and parallelism, to become an efficient system in supporting customized palatal expanders [12].

In some adult patients, a single expansion screw may not provide optimal results. Although purely bone-borne MARPE cases without any tooth-borne anchorage were already introduced, this case suggested using double RPE screws called Tandem Skeletal expander (TSE); both were anteriorly and posteriorly to the mini-implants. This has the potential to expand the maxilla more parallel. Moreover, because the palatal vault is narrow and high, the proximity of four miniscrews would force to place the expansion screw not in the centre of the palate. This clinical situation could force the expansion screw to excessive mechanical stress and consequently blockage of a MARPE.

The aim of the following case report is to describe the resolution of a severe transversal skeletal malocclusion using a Tandem Skeletal Expander (TSE) [13] and customized lingual fixed appliance based on the lingual straight wire method in both arches [14,15].

Diagnosis and aetiology

A 30-year-old woman requested an improvement of her smile with no orthognathic surgery. The extra-oral photographs (*figure 1*) show an accentuated mandibular deviation towards the right and a centred dental upper midline with respect to the facial midline. The predominance of the facial lower third and the pronounced mandibular aspect characterized the frontal and profile view. With respect to the Ricketts E-line, both the upper and lower maxillary appeared in a retruded position. From a clinical intraoral investigation (*figure 1*), the patient showed irregular incisors' exposure, moderate dental crowding, with a sagittal weak class I on the right and a Class III on the left side. In the upper arch, the transversal skeletal contraction was severe, with consequent reduced intra-arch diameters: intercanine and intermolar widths were 18.5 and 25.5 mm respectively, causing the presence of black buccal corridors during smile. Moreover, the patient had a reduced overjet and overbite with a tendency

To cite this article: Cremonini F, et al. Severe transverse discrepancy in adult Class III patient: Parallel rapid palatal expansion with a bone-borne tandem expansion screws (TSE) followed by lingual fixed appliance for a non-surgical treatment: A case report. International Orthodontics (2021), https://doi.org/10.1016/j.ortho.2021.11.001

FIGURE 1
Initial extraoral and intraoral photographs

FIGURE 2
Initial dental casts

to an anterior open bite for the increased third lower vertical dimension. The lower dental midline was deviated by 3 mm to the right, the Spee curve was flatted, while the Wilson curve was pronounced (*figure 2*). A panoramic radiograph (*figure 3*) showed impacted third molars. As expected, the cephalometric analysis (table I) conducted on the laterolateral teleradiograph (*figure 3*) revealed a biretrusion of the maxillaries, which present a class III sagittal relationship (Wits appraisal: −6.6 mm), and an hyperdivergent skeletal pattern (MP-SN: 44.9°). The upper incisors have a pronounced labioversion with respect to the palatal plane (U1-PP: 117°), whilst the IMPA falls within a normal range, with just a little compensation to the sagittal malocclusion.

To cite this article: Cremonini F, et al. Severe transverse discrepancy in adult Class III patient: Parallel rapid palatal expansion with a bone-borne tandem expansion screws (TSE) followed by lingual fixed appliance for a non-surgical treatment: A case report. International Orthodontics (2021), https://doi.org/10.1016/j.ortho.2021.11.001

FIGURE 3
Initial panoramic and lateral cephalometric X-rays

Treatment alternatives

To correct the skeletal and dental malocclusion, different treatment options were considered.
The main treatment choice is represented by a combined orthodontic-orthognathic treatment, with a surgically assisted rapid palatal expansion (SARPE) first, to achieve both skeletal and dental ideal result. In this case, a first non-extractive orthodontic phase is necessary to achieve a sufficient decompensation of the sagittal malocclusion and the most suitable condition to the surgery.
Considering the patient's great clockwise mandibular rotation and anterior open bite, an alternative treatment could have considered the first or second premolar extractions. However, the wedge effect concept that extractions lead to a decrease of FVD (Facial vertical dimension) is invalid [16].
Taking into account the patient's request of improving her smile without orthognathic surgery, a miniscrew-assisted rapid palatal expansion followed by a non-extractive orthodontic treatment was chosen.

Treatment objectives

The primary objective was the orthopaedic correction of severe transverse constriction of the maxilla by a skeletal palatal expansion with minimum dental compensation. Then, the list of objectives we aimed to achieve with fixed lingual appliance included: molar and canine class I, resolution of the crowding, anterior light contact with ideal overjet and overbite, and improvement of facial aesthetic reducing the projection of upper incisors.

Treatment progress

Firstly, as the initial CBCT revealed a close contact of 3.8's both roots with the inferior alveolar nerve, a coronectomy was performed as the complete removal of the tooth would have caused a possible nerve damage (*figure 4*), [17].
After a thorough analysis of the initial records, a two-phase treatment was planned. In the first phase there was a need to obtain orthopaedic correction of the transverse deficiency in the upper arch and decompensation of the Wilson Curve in the lower arch, followed by a second phase with all the other objectives previously set.

FIGURE 4
Panoramic radiograph after the 38 coronectomy

To cite this article: Cremonini F, et al. Severe transverse discrepancy in adult Class III patient: Parallel rapid palatal expansion with a bone-borne tandem expansion screws (TSE) followed by lingual fixed appliance for a non-surgical treatment: A case report. International Orthodontics (2021), https://doi.org/10.1016/j.ortho.2021.11.001

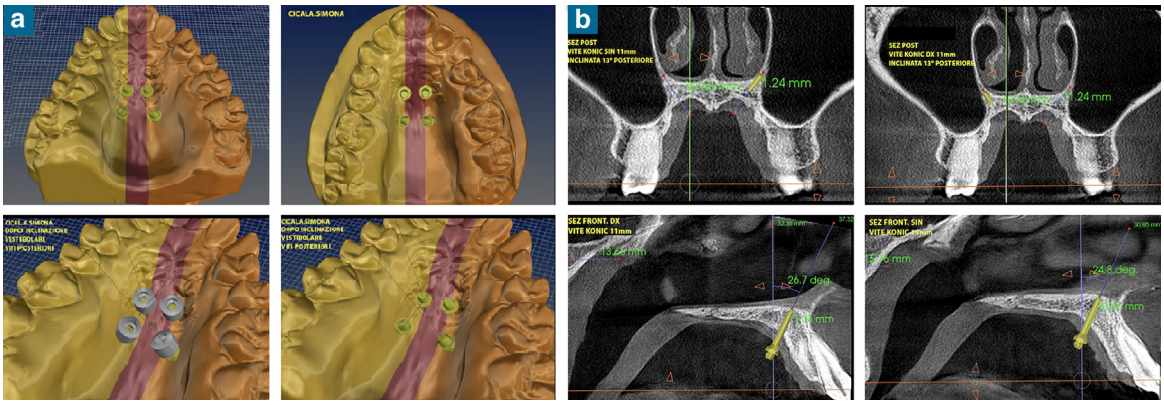

Figure 5

Virtual planning

a: miniscrew insertion sites based on Digital Imaging and Communication in Medicine (DICOM) and stereolithographic (STL) files.
b: Inclination and position of miniscrew insertion using DICOM images.

The palatal thickness and width were precisely studied on the Cone Beam Computed Tomography (CBCT) superimposed onto the stereolithographic (STL) image of the digital model. The safest anteroposterior sites to insert the four miniscrews were identified to ensure a tricortical anchorage; a 3D surgical guide was then printed based on the MAPA system (*figure 5*a).
Once the four miniscrews of 11 mm length and 2 mm diameter (Spider Screw, HDC SRL, Thiene, Italy) were inserted according to the digital planning (*figure 5*b), a pure Skeletal Expander (TSE) was digitally designed and fabricated from the polyvinyl siloxane impression of the upper arch.

The peculiarity of the TSE is that it is formed by two 8 mm expansion screws (Forestadent, Pforzheim, Germany), one at the back and one at the front, which have to be activated simultaneously (*figure 6*), reaching a potential expansion of the middle palatine suture in its entire length, thus obtaining a more parallel expansion than that which could have been obtained with a single expansion screw.
The protocol we used was consequently 40-day activation, i.e., an 8 mm expansion of the screw, one round of activation for each expansion screw. In the meantime, a lingual fixed appliance was bonded in the lower arch in order to start the decompensation of the Wilson Curve and move forward with the alignment phase (*figure 7*).

Figure 6

Tandem Skeletal expander (TSE)

Figure 7

Lower lingual bonding

To cite this article: Cremonini F, et al. Severe transverse discrepancy in adult Class III patient: Parallel rapid palatal expansion with a bone-borne tandem expansion screws (TSE) followed by lingual fixed appliance for a non-surgical treatment: A case report. International Orthodontics (2021), https://doi.org/10.1016/j.ortho.2021.11.001

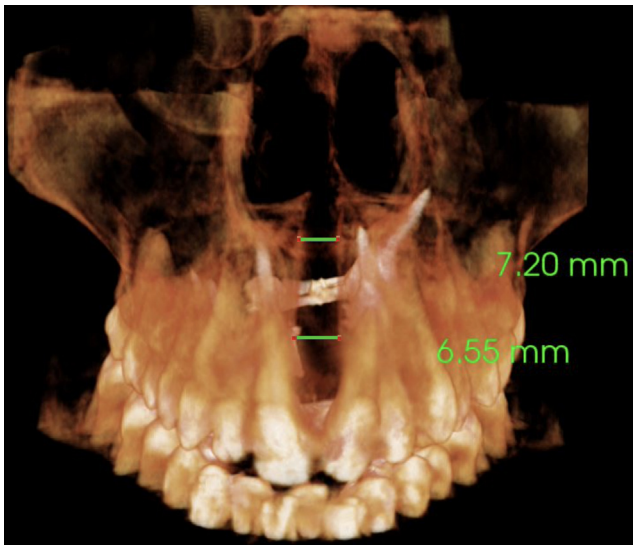

FIGURE 8

CBCT image showing the parallel opening of the midpalatal suture after expansion

As the maxillary contraction was severe, a second TSE was planned to overcorrect the transversal diameters of the upper arch. The activation protocol still comprised one round for each expansion screw per day, up to the maximum allowed. At the end of this first orthopaedic phase, the palatal vault changed its aspect, becoming wider in all its length. The expansion reached is totally skeletal, confirmed by the wide opening of the anterior diastema. As *figure 8* shows that the 8 mm of expansion of the two screws, produced the opening of 7.20 mm in the posterior and 6.55 mm in the anterior areas of the midpalatal suture.

Unfortunately, during the activation of the second expander, the two miniscrews on the right folded, loosing part of their rigidity and straightness (*figure 9*a). However, the upper jaw CBCT performed at the end of the expansion (*figure 9*b) highlighted that the opening of the median palatal suture was consistent and parallel through its length (6.9 mm in average). The amount of pure skeletal expansion was also very clear from the pre- and post- comparison of the upper jaw CBCT.

In just two months, the severe open bite caused by an interference of the right upper second molar improved thanks to the partial relapse of the upper expansion and the achievement of the alignment in the lower arch.

New digital scans were taken in order to start the second phase of treatment and plan the indirect bonding of the upper lingual appliance, given the aesthetic needs of the patient. The same archwire sequence was conducted in both arches: 0.012 CuNiTi and 0.014 CuNiTi for the alignment phase, 0.016 × 0.016 CuNiTi and 0.018 × 0.018 CuNiTi for the levelling and coordination phase. High collaboration with right sized class III elastics was requested in the working phase to achieve good bicuspid contacts, molar class I and an improved centring of the dental midlines. A finishing phase was carried out with numerous bends on 0.0175 × 0.0175 TMA arcs to give first- second- and third order information where necessary. A Class III molar relationship tendence remained on the left side, due to the mandibular shift to the right. A possible correction was the possibility of inserting a miniscrew placed on the left side of the mandible and performing a total distalization. The midline and left posterior relation would have improved, but it would have been only a dentoalveolar compensation, not a solution to the skeletal asymmetry.

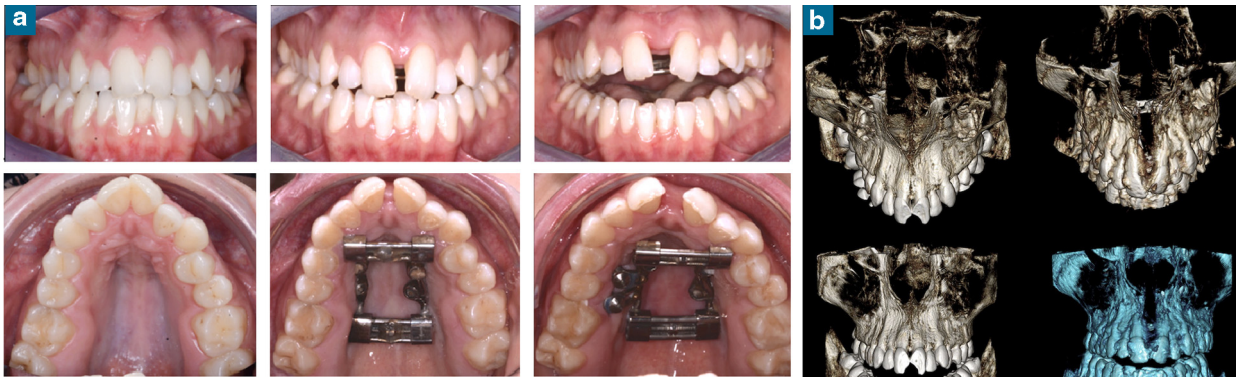

FIGURE 9

Comparison pre- post-expansion

a: Frontal and upper occlusal view at the beginning of treatment, at the end of the first expansion and at the end of the second expansion.
b: CBCT pre- and post-treatment.

To cite this article: Cremonini F, et al. Severe transverse discrepancy in adult Class III patient: Parallel rapid palatal expansion with a bone-borne tandem expansion screws (TSE) followed by lingual fixed appliance for a non-surgical treatment: A case report. International Orthodontics (2021), https://doi.org/10.1016/j.ortho.2021.11.001

After 21 months from the first expander bonding, the orthodontic appliance was removed, and a fixed lingual retainer was added in the upper arch, in addition to removal essix to wear at night in the lower arch.

Treatment result

At the end of the orthodontic treatment, extraoral examination highlighted a great improvement of the overall aesthetic and smile appearance, thanks to the total elimination of lateral black corridors and the achieved ideal incisors' exposure. The skeletal mandibular deviation towards right was inevitably still present, whilst the profile has improved thanks to a better projection of the upper lip after expansion (*figure 10*).

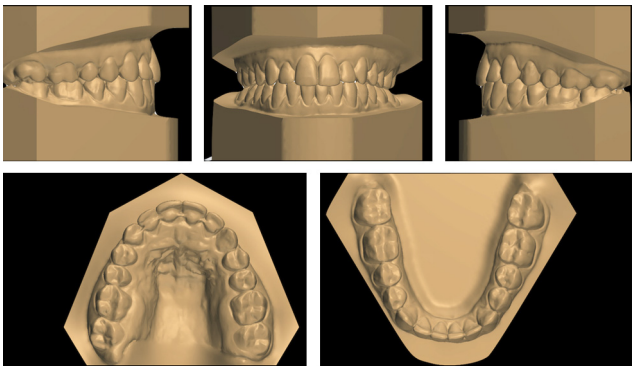

FIGURE 11
Final dental casts

FIGURE 10
Final extraoral and intraoral photographs

To cite this article: Cremonini F, et al. Severe transverse discrepancy in adult Class III patient: Parallel rapid palatal expansion with a bone-borne tandem expansion screws (TSE) followed by lingual fixed appliance for a non-surgical treatment: A case report. International Orthodontics (2021), https://doi.org/10.1016/j.ortho.2021.11.001

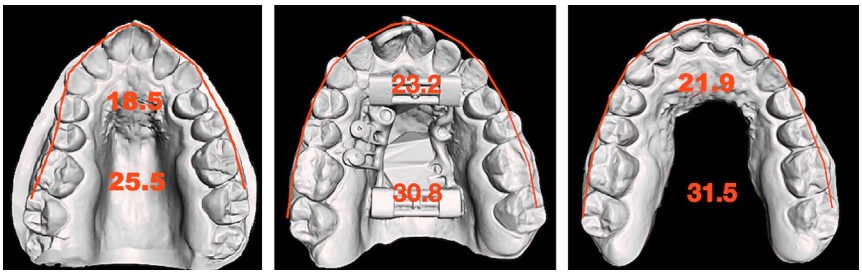

FIGURE 12

A-C. Maxillary transverse width before the beginning of treatment, at the end of the first orthopaedic phase and at the end of the lingual orthodontic treatment

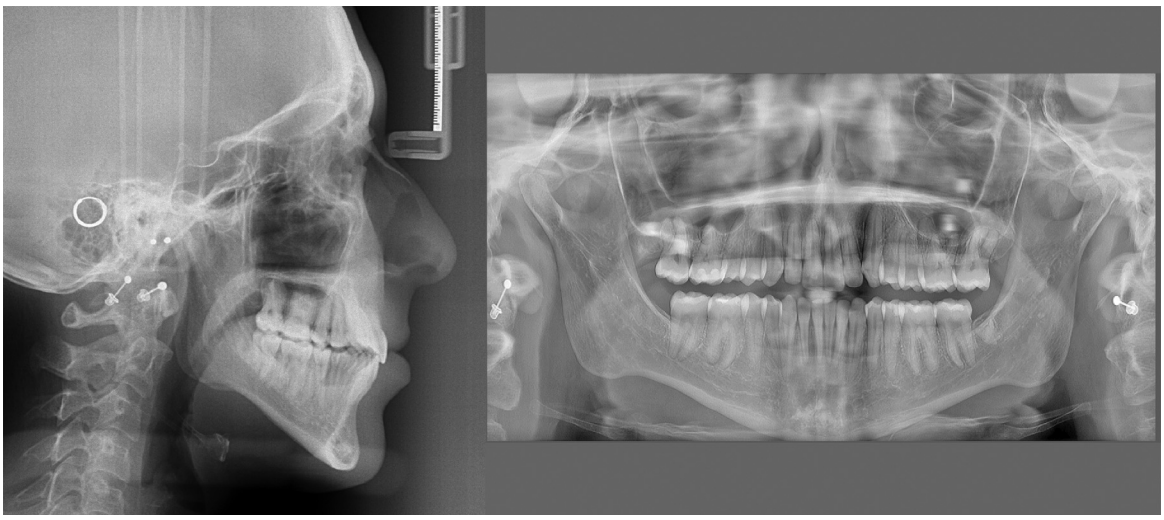

FIGURE 13

Final panoramic and lateral cephalometric X-rays

Even though we appreciated on intraoral examination that partial dental compensation of the deviation of the mandibular skeleton was achieved, the centring of the lower midline to the upper was not perfect. Indeed, the sagittal relationship of class I was obtained on both sides, although it remains weak on the left at the end of the treatment.

The arches were aligned and levelled on the vertical plane, with a correct anterior light contact thanks to the achieved ideal anterior overjet and overbite ratios (*figure 10*).

As the final dental casts confirmed (*figure 11*), the severe transversal constriction of the upper arch was corrected, with the resolution of the initial bilateral crossbite.

The transversal canine and molar diameters increased after skeletal expansion, and then stabilized after orthodontic treatment. A wider and more oval dental arch form resulted from the pure skeletal expansion obtained (*figure 12*).

On the final panoramic radiograph, the remains of the previously extracted impacted third molars could be seen. The cephalometric analysis done on the final latero-lateral teleradiography (*figure 13*) highlighted a slight improvement of skeletal class III (Wits: −4,2 mm). Thanks to the great increase of space availability after maxillary expansion, the upper incisors alignment was performed with a normalization of their inclination with respect to the palatal plane (U1-pp: 111.3°). A slight inferior dental Class III compensation is confirmed from the decrease of IMPA value (*table I*).

Superimpositions of pre- and post-treatment cephalometric tracings, generated according to the methodology developed

To cite this article: Cremonini F, et al. Severe transverse discrepancy in adult Class III patient: Parallel rapid palatal expansion with a bone-borne tandem expansion screws (TSE) followed by lingual fixed appliance for a non-surgical treatment: A case report. International Orthodontics (2021), https://doi.org/10.1016/j.ortho.2021.11.001

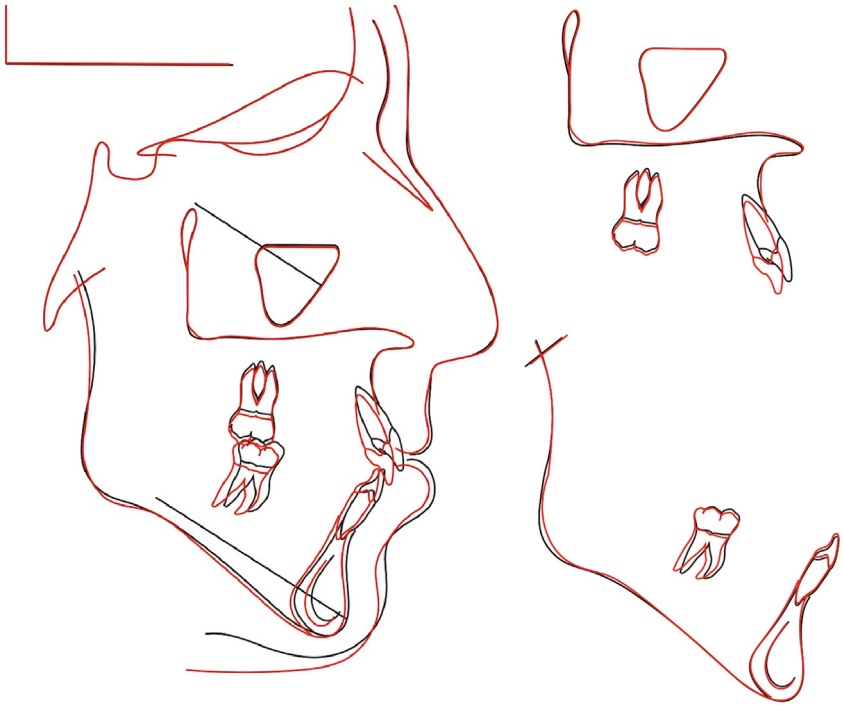

FIGURE 14

Structural general and local superimpositions of Pr. Arne Björk (stable anatomical structures of the anterior cranial base: • The inner contour of the anterior wall of the sella turcica. • The mean intersection point of the lower contours of the anterior clinoid processes and the contour of the anterior wall of saddle, i.e., Walkers's point. • The anterior contours of the middle cranial fossae. The contours of the bilateral fronto-ethmoidal crests. • The cerebral surfaces of the orbital roofs. Stable structure in the maxilla: The anterior contour of the zygomatic process). Stable structures of the mandible: • The anterior contour of the chin. • The inner cortical structure at the inferior border of the symphysis. • Trabecular structures related to the mandibular canal.)

FIGURE 15

1-year follow up intraoral photographs

To cite this article: Cremonini F, et al. Severe transverse discrepancy in adult Class III patient: Parallel rapid palatal expansion with a bone-borne tandem expansion screws (TSE) followed by lingual fixed appliance for a non-surgical treatment: A case report. International Orthodontics (2021), https://doi.org/10.1016/j.ortho.2021.11.001

Table I
Comparison of cephalometric values before and after treatment.

Horizontal skeletal	Norm	Pretreatment	Posttreatment
SNA (°)	82.0 ± 3.5	77.8	81.8
SNB (°)	80.0 ± 3.0	75.7	77.3
ANB (°)	2.0 ± 2.4	2.3	4.4
Maxillary Skeletal (A-Na Perp) (mm)	0.0 ± 3.1	−1.0	−1.5
Mand. Skeletal (Pg-Na Perp) (mm)	−4.0 ± 5.3	−4.9	−10.2
Wits appraisal (mm)	0.0 ± 1.0	−6.6	−4.2
Vertical skeletal	Norm	Pretreatment	Posttreatment
FMA (MP-FH) (°)	26.6 ± 5.0	33.3	35.4
MP - SN (°)	33.0 ± 6.0	44.9	42.2
Palatal-Mand Angle (°)	28.0 ± 6.0	31.0	32.7
Palatal-Occ Plane (PP-OP) (°)	10.0 ± 4.0	11.7	13.9
Mand Plane to Occ Plane (°)	17.4 ± 5.0	19.4	18.8
Anterior dental	Norm	Pretreatment	Posttreatment
U-Incisor Protrusion (U1-APo) (mm)	6.0 ± 2.2	9.0	5.9
L1 Protrusion (L1-APo) (mm)	2.0 ± 2.3	5.3	3.3
U1 - Palatal Plane (°)	110.0 ± 5.0	117.1	111.3
U1 - Occ Plane (°)	57.5 ± 7.0	51.2	54.8
L1 - Occ Plane (°)	72.0 ± 5.0	71.1	73.8
IMPA (°)	95.0 ± 7.0	89.6	87.4

by Arne Bjork [18,19], confirmed the dento-alveolar corrections (*figure 14*) and the inclination of the upper incisor has been reduced until its normalisation.

One-year follow up intra-oral photographs highlighted the great stability of the skeletal expansion performed. The class I intercuspation has also improved, especially in the left size, with closer occlusal contacts (*figure 15*).

Discussion

The evidence of the efficacy of rapid maxillary expansion is strongly related to the age in which the orthopaedic expansion is performed [20]. To obtain a satisfactory result, the skeletal expander has to be effective not only in separating the midpalatal suture, but also the circummaxillary sutures. These structures show greater resistance to expansion with age; thus, in adult patients RPE produces predominantly dentoalveolar effects, and may cause severe periodontal damages [21]. In the previous case report, it was shown that miniscrews-assisted RPE could offer an alternative approach for expanding the basal bone without surgical intervention in adult patients with a pure skeletal anchorage.

In this regard, Lim et al. [9] showed that the proportion of skeletal expansion immediately after the end of the activation with MARPE, was comparable to that previously reported in adolescents with tooth-borne RPE and after SARPE. However, because of the resistance of the midpalatal and circummaxillary structures during expansion, stress would continue to increase until the opening of the midpalatal suture, which might result in dental and alveolar tipping, and deformation of the appliance. For this reason, planning the position of the four miniscrews on the CBCT represents the only way to ensure a stable skeletal anchorage to support the application of the great forces needed to open the midpalatal suture in an adult patient [11]. To have a higher primary stability and lower risk of bending in the

To cite this article: Cremonini F, et al. Severe transverse discrepancy in adult Class III patient: Parallel rapid palatal expansion with a bone-borne tandem expansion screws (TSE) followed by lingual fixed appliance for a non-surgical treatment: A case report. International Orthodontics (2021), https://doi.org/10.1016/j.ortho.2021.11.001

activation of the appliance, we research a tricortical anchorage in the initial planning, by involving the palatal plate, the cortical of the maxillary sinus and last the nasal floor.

The appliance chosen is called Tandem Skeletal Expander and is characterized by the simultaneous presence of two expansion screws, supported by four miniscrews inserted with a 3D surgical guide, properly fitting the palate morphology (MAPA System), [11]. The four miniscrews digital planification on the initial CBCT gains great importance in this case where the palatal vault is narrow and high. As the palatal configuration forced to inserted the four miniscrews with an increased inclination and very closed to each other, the use of a single expansion screw off-centred in the palate could have exposed the appliance to excessive mechanical stress [12]. The advantage of the TSE respect to other MARPE, is that overcomes these biomechanical difficulties and allows an increased resistance to deformation because of the presence of two off-centre expansion screws [13].

The expansion screws are activated in the same time to obtain a parallel opening of the median suture in all its length, as the CBCT performed after confirms (*figure 13*).

1-year follow up confirmed the great stability of the final outcomes and suggested that a pure bone-borne expander could be used as an effective tool for correcting maxillomandibular transverse discrepancies in young adults. This is also confirmed by previous studies which analysed cone-beam computed tomography (CBCT) images acquired before, immediately after and 1 year after expansion [9].

Conclusions

The Tandem Skeletal Expander design and the expansion protocol applied allowed to obtain a significant and stable skeletal increase of transversal diameters, with lower risks and costs than other surgical approaches.

The CBCT control after expansion confirms that the opening of midpalatal suture was obtained in all its length, with a parallel and stackable trend from the anterior to the posterior maxillary region.

The digital planning of the insertion of miniscrews first and the lingual bonding next represented a key factor for the treatment's success.

Francesca Cremonini: is responsible for the treatment planning decision and clinical patient treatment; did the article text production.

Maria Cristina Ansaloni: clinical patient treatment.

Antonio Cremonini: clinical patient treatment.

B. Giuliano Maino: contributed in the treatment planning decision.

Emanuele Paoletto: orthodontic technician.

Federica Pellitteri: did the article text production.

Luca Lombardo: Contributed in the treatment planning decision and clinical patient treatment.

Disclosure of interest: the authors declare that they have no competing interest.

References

[1] Zhou Y, Long H, Ye N, et al. The effectiveness of non-surgical maxillary expansion: a meta-analysis. Eur J Orthod 2014;36(2):233–42.

[2] Baccetti T, Franchi L, Cameron CG, McNamara Jr JA. Treatment timing for rapid maxillary expansion. Angle Orthod 2001;71(5):343–50.

[3] Lione R, Franchi L, Cozza P. Does rapid maxillary expansion induce adverse effects in growing subjects? Angle Orthod 2013;83(1):172–82.

[4] Garib DG, Henriques JF, Janson G, de Freitas MR, Fernandes AY. Periodontal effects of rapid maxillary expansion with tooth-tissue-borne and tooth-borne expanders: a computed tomography evaluation. Am J Orthod Dentofacial Orthop 2006;129(6):749–58.

[5] Koudstaal MJ, Poort LJ, van der Wal KG, Wolvius EB, Prahl-Andersen B, Schulten AJ. Surgically assisted rapid maxillary expansion (SARME): a review of the literature. Int J Oral Maxillofac Surg 2005;34(7):709–14.

[6] Lanigan DT, Mintz SM. Complications of surgically assisted rapid palatal expansion: review of the literature and report of a case. J Oral Maxillofac Surg 2002;60(1):104–10. http://dx.doi.org/10.1053/joms.2002.29087.

[7] Lee KJ, Park YC, Park JY, Hwang WS. Miniscrew-assisted nonsurgical palatal expansion before orthognathic surgery for a patient with severe mandibular prognathism. Am J Orthod Dentofacial Orthop 2010;137(6):830–9.

[8] Cantarella D, Dominguez-Mompell R, Mallya SM, et al. Changes in the midpalatal and pterygopalatine sutures induced by micro-implant-supported skeletal expander, analyzed with a novel 3D method based on CBCT imaging. Prog Orthod 2017;18(1):34.

[9] Lim HM, Park YC, Lee KJ, Kim KH, Choi YJ. Stability of dental, alveolar, and skeletal changes after miniscrew-assisted rapid palatal expansion. Korean J Orthod 2017;47:313–22.

[10] Carlson C, Sung J, McComb RW, Machado AW, Moon W. Microimplant-assisted rapid palatal expansion appliance to orthopedically correct transverse maxillary deficiency in an adult. Am J Orthod Dentofacial Orthop 2016;149(5):716–28.

[11] Maino BG, Paoletto E, Lombardo 3rd L, Siciliani G. A three-dimensional digital insertion guide for palatal miniscrew placement. J Clin Orthod 2016;50(1):12–22.

[12] Lombardo L, Carlucci A, Maino BG, Colonna A, Paoletto E, Siciliani G. Class III malocclusion and bilateral cross-bite in an adult patient treated with miniscrew-assisted rapid palatal expander and aligners. Angle Orthod 2018;88(5):649–64. http://dx.doi.org/10.2319/111617-790.1.

To cite this article: Cremonini F, et al. Severe transverse discrepancy in adult Class III patient: Parallel rapid palatal expansion with a bone-borne tandem expansion screws (TSE) followed by lingual fixed appliance for a non-surgical treatment: A case report. International Orthodontics (2021), https://doi.org/10.1016/j.ortho.2021.11.001

[13] Maino BG, Paoletto E, Cremonini F, Liou E, Lombardo L. Tandem skeletal expander and MAPA protocol for palatal expansion in adults. J Clin Orthod 2020;54(11):690–704.
[14] Takemoto K, Scuzzo G, Lombardo LU, Takemoto YU. Lingual straight wire method. Int Orthod 2009;7(4):335–53.
[15] Kairalla SA, Scuzzo G, Triviño T, Velasco L, Lombardo L, Paranhos LR. Determining shapes and dimensions of dental arches for the use of straight-wire arches in lingual technique. Dental Press J Orthod 2014;19(5):116–22.
[16] Kim TK, Kim JT, Mah J, Yang WS, Baek SH. First or second premolar extraction effects on facial vertical dimension. Angle Orthod 2005;75(2):177–82.
[17] Cervera-Espert J, Pérez-Martínez S, Cervera-Ballester J, Peñarrocha-Oltra D, Peñarrocha-Diago M. Coronectomy of impacted mandibular third molars: A meta-analysis and systematic review of the literature. Med Oral Patol Oral Cir Bucal 2016;21(4):e505–13.
[18] Björk A, Skieller V. Growth of the maxilla in three dimensions as revealed radiographically by the implant method. Br J Orthod 1977;4(2):53–64.
[19] Björk A. Prediction of mandibular growth rotation. Am J Orthod 1969;55(6):585–99.
[20] Kwak KH, Kim SS, Kim YI, Kim YD. Quantitative evaluation of midpalatal suture maturation via fractal analysis. Korean J Orthod 2016;46(5):323–30. http://dx.doi.org/10.4041/kjod.2016.46.5.323.
[21] Suri L, Taneja P. Surgically assisted rapid palatal expansion: a literature review. Am J Orthod Dentofacial Orthop 2008;133(2):290–302.